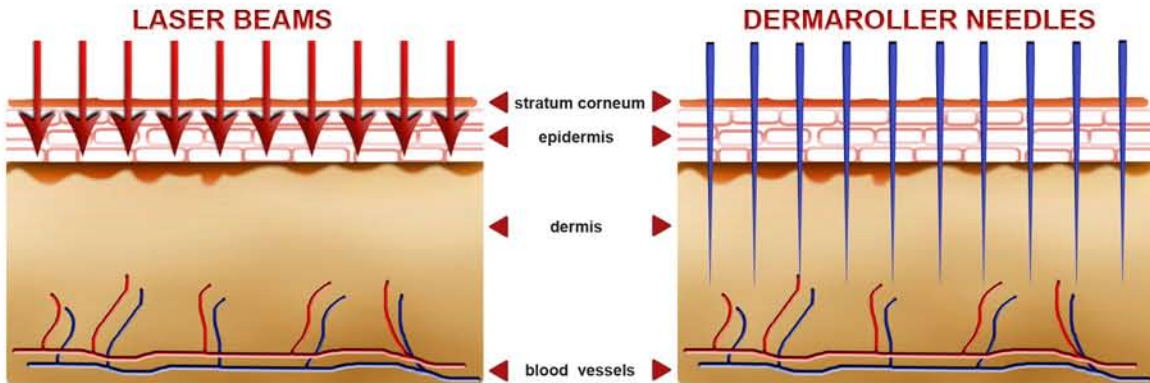
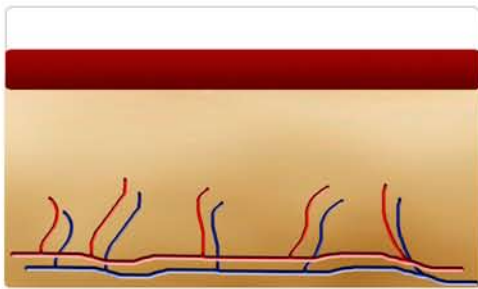


ALBATIVE TECHNIQUES VS DERMAROLLER

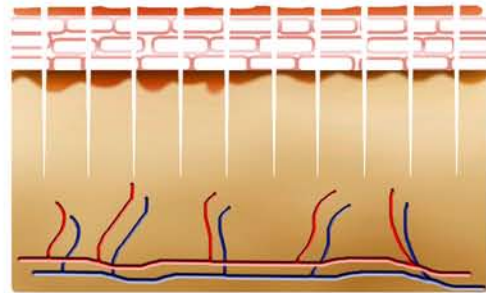


- Laser and acid evaporate the epidermis

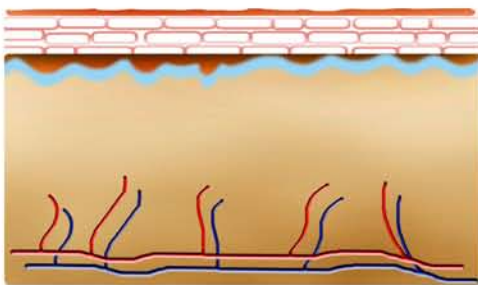
- Fine needles prick through epidermis and dermis



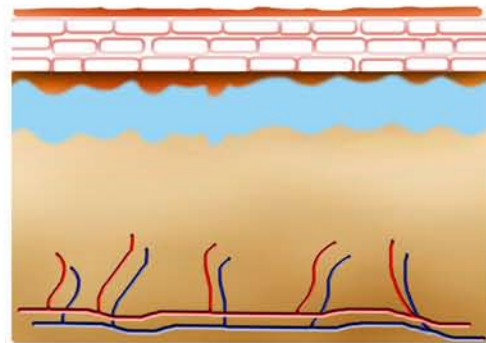
- A second degree burn wound is set. Inflammation, profiaration and maturation can take a month



- Pricking channels close within 1 hour. Skin and epidermis stay intact. Healing process starts immediately!



- A new, relatively thin collagen layer grows. The skin in total becomes thinner. A second treatment in general is not possible



- A new and additional collagen layer is set close to the corium. The skin becomes thicker. Treatment can be repeated many times